

*Comparative pilot study of implantation techniques for pudendal neuromodulation: technical and clinical outcome in first 20 patients with chronic pelvic pain*

**K. Heinze, R. Hoermann, H. Fritsch,  
R. Dermietzel & A. van Ophoven**

**World Journal of Urology**

ISSN 0724-4983

World J Urol

DOI 10.1007/s00345-014-1304-7



**Your article is protected by copyright and all rights are held exclusively by Springer-Verlag Berlin Heidelberg. This e-offprint is for personal use only and shall not be self-archived in electronic repositories. If you wish to self-archive your article, please use the accepted manuscript version for posting on your own website. You may further deposit the accepted manuscript version in any repository, provided it is only made publicly available 12 months after official publication or later and provided acknowledgement is given to the original source of publication and a link is inserted to the published article on Springer's website. The link must be accompanied by the following text: "The final publication is available at [link.springer.com](http://link.springer.com)".**

# Comparative pilot study of implantation techniques for pudendal neuromodulation: technical and clinical outcome in first 20 patients with chronic pelvic pain

K. Heinze · R. Hoermann · H. Fritsch · R. Dermietzel ·  
A. van Ophoven

Received: 3 December 2013 / Accepted: 10 April 2014  
© Springer-Verlag Berlin Heidelberg 2014

## Abstract

**Purpose** Neurostimulation of the pudendal nerve (PN) is considered for patients who have failed sacral neuromodulation. Previous techniques for PN localization are described to be uncomplicated and promise to achieve accuracy in electrode placement. However, in clinical use, they appear challenging. We developed a puncture technique using fixed anatomical landmarks for a fast and reproducible localization of the PN.

**Methods** Full-body cadavers and dissected anatomical preparations were studied for the course of the PN. Fluoroscopically controlled fixed anatomical landmarks locating the pudendal trunk were defined. Lead placement following established techniques was performed, and the topographic relationship to the PN was documented by dissection. In a pilot series of 20 patients with chronic pelvic pain, pudendal neuromodulation (PNM) was performed uni- and bilateral using the different approaches. Technical and clinical outcomes of the various techniques were compared.

**Results** Fixed anatomical landmarks such as ischial spine, ischial tuberosity, acetabulum and anal rim resulted in a right-angled triangle with a new start and target point for puncture. Initials of the landmarks add up to the teaching

acronym STAR. STAR technique including a puncture angle of 60° and a gluteal lead exit places 3–4 electrode poles at the nerve. In clinical trial, mean operation time for bilateral PNM in STAR was 85 min with mean puncture attempts of 3.5 to reach the nerve. Pain decreased statistically significant only in bilateral PNM.

**Conclusions** The STAR approach appears to achieve technical standardisation and optimized reproducibility in pudendal lead placement resulting into an increased feasibility of PNM.

**Keywords** Pudendal neuromodulation · Pudendal nerve · Puncture technique · Sacral neuromodulation

## Introduction

Sacral neuromodulation (SNM) is a well-established procedure for the treatment of dysfunction of the lower urinary tract, e.g. idiopathic detrusor overactivity, urinary retention, urge incontinence, symptoms of chronic pelvic pain and faecal incontinence [1]. About 10–25 % of patients fail to respond to SNM [2]. The search for an alternative treatment has led to the stimulation of the pudendal nerve (PN). Precondition for a successful pudendal neuromodulation (PNM) is the accurate placement of the tined lead at the nerve, especially at the trunk of the nerve. The current literature encompasses three puncture techniques, which are described as uncomplicated and fast in use.

In 1989, Schmidt et al. described for the first time a puncture technique to arrive the PN for stimulation or block [3]. This technique was modified by Spinelli et al. [4]. An alternative technique was described by Peters et al. in 2005 [5]. The third technique was described by Bock in

K. Heinze (✉) · A. van Ophoven  
Department of Neuro-Urology, Marienhospital Herne, Herne,  
Germany  
e-mail: kai.heinze@marienhospital-herne.de

R. Hoermann · H. Fritsch  
Department of Anatomy, Histology and Embryology, University  
of Innsbruck, Innsbruck, Austria

R. Dermietzel  
Department of Neuroanatomy and Molecular Brain Research,  
University of Bochum, Bochum, Germany

2010 using the same anatomical landmarks as described by Spinelli with the surgeon's gloved index finger placed inside the rectum to guide the needle to the PN [6]. In daily use, the described techniques unmask as very challenging and time consuming because repeated puncture attempts are often necessary to find the PN.

One of the major characteristics of some of these techniques is that they are based on anatomical landmarks that are variable under fluoroscopical control because they depend on patients' individual anatomy and intraoperative bedding (e.g. trochanter major). We developed an implantation technique based on fixed anatomical landmarks to define the ischial spine and thus the trunk of the PN in order to achieve a fast and reproducible locating of the nerve and to increase feasibility of PNM.

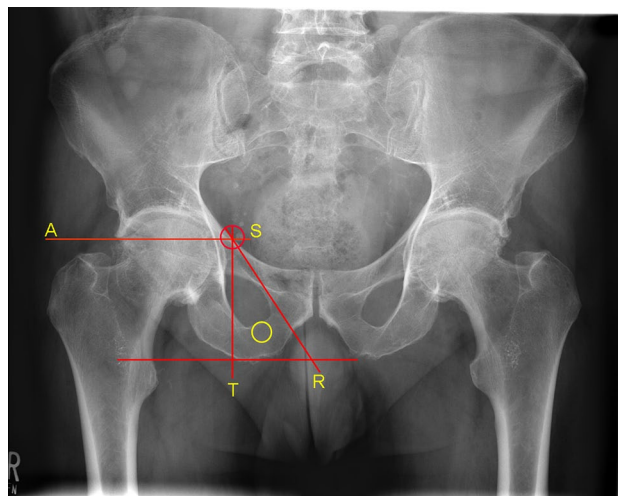
Finally, we transferred our new approach from bench to bedside and compared the technical and clinical outcomes of the various techniques in 20 patients with chronic pelvic pain syndrome.

## Materials and methods

### Implantation technique

We utilized three full-body cadavers and six anatomical preparations of the pelvis provided by the Anatomical Institutes at the Universities of Innsbruck, Austria, and Bochum, Germany in order to re-examine the anatomical course of the PN and to confirm the ischial spine as the bony lead structure directly located at the pudendal trunk. The semilunar acetabulum was positioned consistently on ischial spine level. Thus, a horizontal line crossing the middle of the acetabulum (A) is drawn on skin surface as the first step. A vertical line crosses the centre of the ischial tuberosity (T) caudally. The junction of these two lines pinpoints the ischial spine (S). A line running in parallel to the acetabulum line (A) is drawn touching the bottom of the ischial tuberosity. This line hits the anal rim (R) on the skin side. Marking and connecting points (T), (R) and (S) by straight lines on skin surface will result into a right-angled triangle. The centre of this STAR triangle, i.e. the junction of the 3 bisecting lines serves as the starting point for puncture. The target area for the tip of the puncture needle is the apical corner of the triangle, i.e. the trunk of the PN (Fig. 1).

We affirmed our new approach using six dissected pelvic preparations and three nonprepared full cadavers and compared the results with the previously described implantation techniques. Under fluoroscopical control, we placed tined leads following the described techniques on the cadavers and documented the topographic relationship of the poles to the PN by dissection.



**Fig. 1** Fixed anatomical landmarks result into a triangle on skin surface, the initials of the different landmarks add up to the STAR acronym (S ischial spine, T ischial tuberosity, A Acetabulum, R anal rim). The junction of the bisecting lines serves as the starting point for needle puncture (yellow circle), the apical tip of the triangle pinpoints the spina, i.e. the anatomical area of the trunk of the PN (red circle)

### Pilot study

The study protocol was approved by the ethics committee of the Ruhr-University of Bochum on March 2011 (registration number: 3919-11) prior to the study. Written informed consent was obtained from all participants.

In a prospective clinical proof-of-concept trial, we implanted tined leads at the PN in 20 patients presenting with chronic pelvic pain syndromes (CPPS). Patients suffering from bladder pain syndrome were diagnosed following ESSIC criteria [7]. Patients fulfilling at least three out of the five essential Nantes criteria were diagnosed with pudendal neuralgia [8]. Disease-specific pain intensity was detected using a visual analogue scale in millimetre. The various operations were performed by a single surgeon, who was trained in SNM to minimize further operation time after lead placement at the PN such as lead tunnelling, preparing one or two supragluteal pockets, etc.

Using STAR approach, patients were placed in prone position with an elevation of the buttock of about 40°. Guided by STAR triangle implantation was performed under monitoring of pudendal nerve terminal motor latency (PNTML) to verify contact to the PN. The other operations were technically performed as described in the quoted papers. Number of trials to successfully reach the nerve, time to place an electrode at the nerve and total operation time were documented. Proximity and number of poles to the PN were defined by the characteristic neurophysiological pudendal signal with a PNTML <2.5 ms in combination with an anal wink using a stimulation amperage of



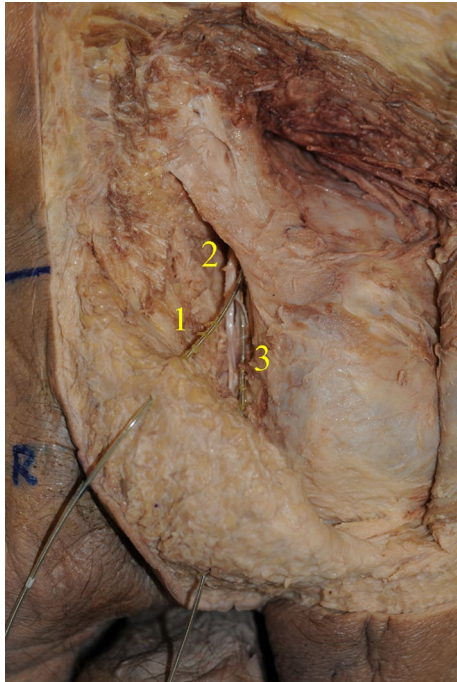
<5.0 mA. If technically feasible, puncture attempts aimed for bilateral identification of the PN and for bilateral electrode implantation. If PNTML signals were poor or indistinctive or time for surgery accumulated excessively, thus impeding bilateral implantation, the patient's side with the best neurophysiological and motoric signal was chosen for unilateral lead implantation.

After a test period of 4 weeks, changes in pain intensity were documented and the clinical outcomes of unilateral PNM and bilateral PNM were compared.

## Results

### Implantation technique

Pelvic dissection of the full cadavers revealed a direct contact of the electrodes placed in STAR technique alongside the trunk of the PN. The poles were located under the ischial spine in backing of the sacrospinal ligament and the tined lead checks rested in the ischiorectal fat tissue. Three poles of the quadripolar lead were in direct contact with the PN (Fig. 2). The skin exit of the electrode was gluteal with a puncture angle of about 50°–60° (Table 1).



**Fig. 2** Meticulous dissection of full-body cadavers after implantation of quadripolar electrodes following STAR technique revealed 3–4 electrode poles (1) alongside the trunk of the pudendal nerve (2) and all tines anchored within the ischiorectal fatty tissue. Note the even more parallel course of the electrode placed in Peters technique (3)

### Pilot study

PNM was performed in 20 patients with CPPS: six patients received implants in Spinelli technique, two patients in Bock technique, two patients in Peters technique and ten patients in STAR technique. Decision for single left- or right-side implantation was based upon best intraoperative PNTML (<2.5 ms) and best motoric response in terms of contraction of the external anal sphincter only if bilateral implantation revealed not feasible.

Each technique achieved a good pudendal signal with a PNTML <2.5 ms and an anal wink using a low stimulation amperage of <5.0 mA. The mean number of poles close to the nerve was two for Spinelli and Bock and three for Peters and STAR (Table 1).

Only STAR and Bock techniques resulted in bilateral electrode placement in all 12 patients. Figure 3 shows an X-ray of a bilateral lead implantation at the pudendal nerve. The mean operation time for bilateral implantation using STAR technique was 85 min compared with a mean of 105 min for a unilateral PNM using the three alternative techniques in ten patients. Mean time to place a lead at either nerve was 25 min using STAR technique, and mean number of puncture attempts for a successful localization of the nerve was 3.5. In contrast, mean time to place a lead at either the right or left nerve was 60 min for the 3 alternative techniques, and the mean number of puncture attempts required to place at least one electrode was 15 (Table 1).

Mean pain intensity was 85 mm at baseline. After 4 weeks of bilateral PNM performed in Bock and STAR technique, mean pain intensity decreased statistically significant from 85 to 40 mm ( $p = 0.018$ ) with an IPG (implanted pulse generator) implantation rate of 90 %. In contrast, after 4 weeks of unilateral PNM performed in Spinelli and Peters technique, pain intensity decreased from 85 to 60 mm ( $p = 0.15$ ).

## Discussion

Neuromodulation for functional diseases of the lower urinary tract has become an effective and well-accepted therapeutic concept. In case SNM has failed, PNM has become an additional option [9]. One basic concept of peripheral PNM is to expand afferent backfiring and thus to stimulate neural contributions from all PN roots S2–S4 [10].

Although the first pudendal puncture technique was already described in 1989 [3], PNM has currently been established only in a few specialized institutions around the world. One reason for the hesitant application of PNM might be that a standardized way for tined lead placement at the PN still does not exist and that localization of the nerve is very challenging without an intraoperative

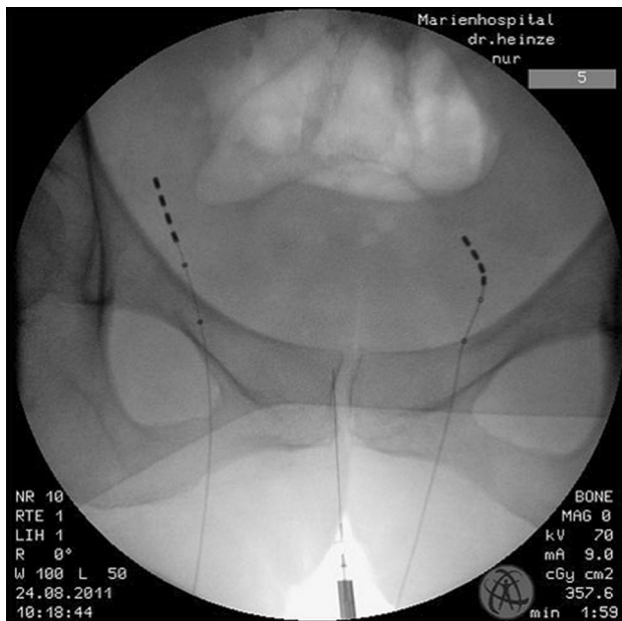
**Table 1** Results of the various implantation techniques for PNM

	Implantation technique			
	Peters	Spinelli	Bock	STAR
<b>Characteristics</b>				
Anatomical landmarks	Ischial tuberosity only	Trochanter major + ischial tuberosity	Trochanter major + ischial tuberosity + index finger inside the rectum	4 Fixed anatomical landmarks
Fluoroscopical monitoring	+	+	–	+
Recording of PNTML/CMAP signal to proof contact to the nerve	+	+	–	+
<b>Results of Cadaveric Study</b>				
Puncture direction in relation to the nerve route	Tangential aiming at ischial spine	Orthogonal aiming at ischial spine	Orthogonal aiming at finger index on rectal branches	Ortho-tangential aiming at ischial spine
Lead exit on skin side surface	Infragluteal/perineal	Supragluteal	Supragluteal	Midgluteal
Max. number of poles alongside nerve	4 Electrodes at trunk of nerve	2–3 Electrodes at trunk of nerve	3 Electrodes at rectal branches	3–4 Electrodes at trunk of nerve
<b>Results of pilot study</b>				
Patient number operated using the different approaches	2	6	2	10
Mean number of puncture attempts for PN localization	15	22	8	3.5
Mean time to place a single electrode at either nerve	51 min	98 min	31 min	25 min
Operation time	90 min for unilateral implant	130 min for unilateral implant	95 min for <i>bilateral</i> implants	85 min for <i>bilateral</i> implants
PNTML (ms)	<2.5	<2.5	<2.5	<2.5
Stimulation amperage to get pudendal signal/ anal wink (mA)	<5.0	<5.0	<5.0	<5.0
Mean number of poles at the pudendal nerve	3	2	2	3
Mean pain intensity on VAS after 4 weeks of PNM (baseline: 85 mm)	60 mm ( $p = 0.15$ )	60 mm ( $p = 0.15$ )	40 mm ( $p = 0.018$ )	40 mm ( $p = 0.018$ )

markable bony lead structure as taught for SNM. During our efforts to overcome the above-mentioned technical and clinical challenges, three important factors for achieving a successful tined lead placement at the PN crystallized:

1. fast, accurate and reproducible locating of the PN,
2. long-distance, i.e. high number contact of electrode poles to the PN
3. tension- and compression-free electrode exit at skin surface.

Precondition for a safe and effective PNM is the correct placement of the tined lead at the trunk of the PN. The ischial spine is the bony lead structure to the PN trunk. Under fluoroscopical control, the imaging of the spina ischiadica in a patient in prone position is challenging and depends on patient's individual anatomy, quality of the X-ray unit and surgeon's experience. Therefore, fixed and fluoroscopically traceable anatomical structures leading to the spine and thus to the trunk of the PN are desirable for successful lead placement.



**Fig. 3** X-ray of implantation result of quadripolar tined leads at the pudendal nerve on both sides. The sphincter EMG needle projects between the leads for deduction of the specific pudendal signal and the PNTML

The technique by Peters uses the tuber ischiadicum as the only landmark to find the ischial spine. The puncture starts 2 cm medial of the tuber in a free direction towards the radiologically suggested spine. We experienced that many attempts were necessary to find the nerve because of the variance with potential deviation of the puncture needle in all three body planes leading to an increase in radiation and operation time.

The techniques by Spinelli and Bock describe the trochanter major as the additional bony lead structures besides the tuber leading to the ischial spine. In our experience, the trochanter major is too variable for guiding to the ischial spine because its position is inconsistent and varies depending on intraoperative bedding of the patient.

Bock uses the above two identical landmarks. Additionally, he puts the index finger into the patient's rectum at the site of the suggested PN to determine best needle position by maximum sphincter contraction during stimulation. In our experience, this technique shows a high level of reproducibility but it also has two important limitations:

1. In patients with high volume buttocks, the index finger is typically too short to reach the trunk of nerve and might thus be placed at the peripheral rectal branches instead.
2. Placing a finger in the patient's rectum during surgery might compromise sterility of operation site and implant components with increased risk of wound infection.

As a result of the perineal implantation approach that allows the electrode to run in parallel to the PN, the technique by Peters typically places the maximum of four poles at the nerve. A high number of electrode poles alongside the nerve will allow for alternating (re-)programming using different pole combinations and will increase the neuromodulative flexibility. Figure 2 shows the direct comparison of the tined leads placed in Peters and STAR techniques at the PN in the cadaver and after dissection.

On the other hand, the lead exit in Peters technique is infragluteal next to the tuber ischiadicum with the full body weight on the electrode while the patient is sitting. However, although no clinical study has assessed the correlation between lead exit and risk for lead migration, in our opinion and our experience a chronic pressure load on the electrode could lead to an increased risk of intrapelvic lead migration and should be avoided.

Creating the STAR approach, we tried to attenuate the above limitations. Therefore, we defined fixed anatomical landmarks that are consistently traceable by fluoroscopy leading to the nerve. Eventually, this technique becomes independent of patient's anatomy and intraoperative bedding. Choosing a gluteal approach to the pelvis, we achieved the combination of a high number of at least three poles alongside the nerve and a reduction in cutaneous pressure load on the lead. However, although not observed in the first implant series, the midgluteal approach might increase risk of bleeding during lead placement and might exert impact on the lead while ambulating compared with an infragluteal or supragluteal approach. It remains to be seen whether this technical aspect will be a drawback in clinical follow-up.

Neuromodulative flexibility will not only be increased by a high number of electrode poles alongside the PN but by bilateral implantation as well. However, the role and value of two electrodes instead of a single unilateral implantation are still under debate for SNM [11]. Regarding PNM for CPPS/pudendal neuralgia, such discussion appears reasonable as well. Recently, unilateral PNM has been described as a promising treatment approach for patients suffering from CPPS/pudendal neuralgia [5, 12] but no study exists presenting the outcomes of bilateral PNM so far. However, experimental and clinical evidence from SNM trials indicates that some individuals only benefit from bilateral stimulation [13, 14]. The outcomes of our pilot series support the impression that a bilateral PNM seems to be superior in pain decrease compared with a unilateral PNM in patients with CPPS/pudendal neuralgia (Table 1).

Furthermore, as a result of the increased surgical standardization with diminished technical challenges, STAR approach decreased time spent in the operating room. Especially, the mean number of puncture attempts (3.5) to reach the PN in our first ten patients operated in STAR technique

demonstrates the steep learning curve using this technique compared to the others. However, we have to recognize that our small patient number in this pilot series is a limitation of this study and that the rapid placement using the STAR approach may be due to the experience we have gained developing this method in the cadaver and may be due to the effect of training operating more patients with our own technique than with the others by a single surgeon.

A further limitation of this study is the lack of comparison in radiation time needed for successful lead implantation. Future comparative studies should include this data as a surrogate outcome parameter to indicate the differences in feasibility of the various implantation techniques. Assessment of radiation time further allows to identify the technique with the lowest radiation exposition for the patient, a consideration that generally favours the Bock approach, because no fluoroscopical control is needed.

Basically, each puncture technique has its own pros and cons, and the successful application of a new technique is often a matter and result of practice and experience. With the new STAR approach, we tried to achieve technical standardization in puncture and lead placement at the PN to make PNM more feasible.

## Conclusion

The STAR approach appears to achieve standardization and reproducibility in lead placement at the PN potentially resulting into an increased feasibility of PNM for the treatment of functional disorders of the lower urinary tract.

**Acknowledgments** This study was awarded at the 22nd annual meeting of the Forum Urodynamicum 2011 in Mönchengladbach with the Eugen-Rehfishch-Prize.

**Conflict of interest** The authors declare that they have no conflict of interest.

**Ethical standard** The study protocol was approved by the ethics committee of the Ruhr-University of Bochum on March 2011 (registration number: 3919-11) prior to the study. Written informed consent was obtained from all participants.

## References

1. Van Kerrebroeck PE, Marcelissen TA (2012) Sacral neuromodulation for lower urinary tract dysfunction. *World J Urol* 30(4):445–450. doi:10.1007/s00345-011-0780-2
2. Bosch JL (2010) An update on sacral neuromodulation: where do we stand with this in the management of lower urinary tract dysfunction in 2010? *BJU Int* 106(10):1432–1442. doi:10.1111/j.1464-410X.2010.09702.x
3. Schmidt RA (1989) Technique of pudendal nerve localization for block or stimulation. *J Urol* 142(6):1528–1531
4. Spinelli M, Malaguti S, Giardiello G, Lazzeri M, Tarantola J, Van Den Hombergh U (2005) A new minimally invasive procedure for pudendal nerve stimulation to treat neurogenic bladder: description of the method and preliminary data. *NeuroUrol Urodyn* 24(4):305–309. doi:10.1002/nau.20118
5. Peters KM, Feber KM, Bennett RC (2005) Sacral versus pudendal nerve stimulation for voiding dysfunction: a prospective, single-blinded, randomized, crossover trial. *NeuroUrol Urodyn* 24(7):643–647. doi:10.1002/nau.20174
6. Bock S, Folie P, Wolff K, Marti L, Engeler DS, Hetzer FH (2010) First experiences with pudendal nerve stimulation in fecal incontinence: a technical report. *Tech Coloproctol* 14(1):41–44. doi:10.1007/s10151-009-0554-7
7. van de Merwe JP, Nordling J, Bouchelouche P, Bouchelouche K, Cervigni M, Daha LK, Elneil S, Fall M, Hohlbrugger G, Irwin P, Mortensen S, van Ophoven A, Osborne JL, Pecker R, Richter B, Riedl C, Sairanen J, Tinzl M, Wyndaele JJ (2008) Diagnostic criteria, classification, and nomenclature for painful bladder syndrome/interstitial cystitis: an ESSIC proposal. *Eur Urol* 53(1):60–67. doi:10.1016/j.eururo.2007.09.019
8. Labat JJ, Riant T, Robert R, Amarengo G, Lefaucheur JP, Rigaud J (2008) Diagnostic criteria for pudendal neuralgia by pudendal nerve entrapment (Nantes criteria). *NeuroUrol Urodyn* 27(4):306–310. doi:10.1002/nau.20505
9. Peters KM, Killinger KA, Boguslawski BM, Boura JA (2010) Chronic pudendal neuromodulation: expanding available treatment options for refractory urologic symptoms. *NeuroUrol Urodyn* 29(7):1267–1271. doi:10.1002/nau.20823
10. Peters KM, Feber KM, Bennett RC (2007) A prospective, single-blind, randomized crossover trial of sacral vs pudendal nerve stimulation for interstitial cystitis. *BJU Int* 100(4):835–839
11. Scheepens WA, de Bie RA, Weil EH, van Kerrebroeck PE (2002) Unilateral versus bilateral sacral neuromodulation in patients with chronic voiding dysfunction. *J Urol* 168(5):2046–2050. doi:10.1097/01.ju.0000034352.91753.a5
12. Carmel M, Lebel M, Tule M (2010) Pudendal nerve neuromodulation with neurophysiology guidance: a potential treatment option for refractory chronic pelvi-perineal pain. *Int Urogynecol J* 21(5):613–616. doi:10.1007/s00192-009-1054-z
13. Kaufmann S, Naumann CM, Hamann MF, Seif C, Braun PM, Junemann KP, van der Horst C (2009) Unilateral vs bilateral sacral neuromodulation in pigs with formalin-induced detrusor hyperactivity. *BJU Int* 103(2):260–263
14. Laurberg S (2011) Sacral nerve stimulation for faecal incontinence: from voodoo to evidence-based medicine. *Colorectal Dis* 13(8):836. doi:10.1111/j.1463-1318.2011.02713.x